

**MEET THE DOCTOR:
KEVIN C LIN, DDS, FACP
PROSTHODONTIST**

RECONSTRUCTIVE DENTAL SPECIALIST

Dr. Kevin Lin is a board-certified specialist in prosthetic dentistry. He has extensive clinical training and experience rehabilitating patients with complex dental problems using composite resin, dental implants, veneers, crowns, bridges, and dentures. He is an expert in creating and maintaining partials and dentures for older adults. Moreover, he has restored thousands of dental implants and related fixed and removable dental appliances.

Dr. Lin has published numerous papers in peer-reviewed journals, written book chapters, and presented in international and national professional conferences and regional study club meetings on issues concerning prosthetic dentistry.

He actively participates in local study clubs to learn and share new clinical knowledge and techniques; he works tirelessly with specialists, general dentists, and lab technicians to provide the best quality patient care possible. He currently serves as an ad-hoc journal reviewer for the Journal of Prosthetic Dentistry and the Journal of Prosthodontics.

Kevin C. Lin, DDS



EDUCATION

Board Certification, American Board of Prosthodontics Certificate in Prosthodontics, UCSF Postgraduate Prosthodontics
Doctor of Dental Surgery, UCLA School of Dentistry
B.S. Biological Sciences in Medical Microbiology & B.A. Psychology, UC Davis

POST-GRADUATE CREDENTIALS

Diplomate, American Board of Prosthodontics
Fellow, American College of Prosthodontists
Fellow, International Congress of Oral Implantologists
Ad-hoc Journal Reviewer, Journal of Prosthetic Dentistry and Journal of Prosthodontics
Assistant Professor, University of the Pacific, Arthur A. Dugoni School of Dentistry
Volunteer Faculty, Pre-doctoral Prosthodontic Clinic, University of California, San Francisco

RECONSTRUCTIVE DENTISTRY UPDATES

JUL/AUG 2020

Evidence Based Clinical Practices in Prosthodontics

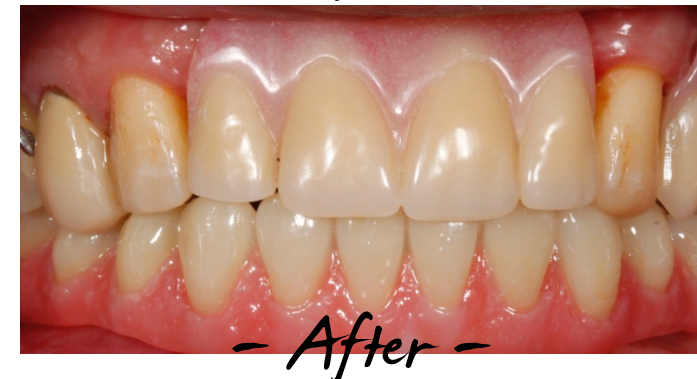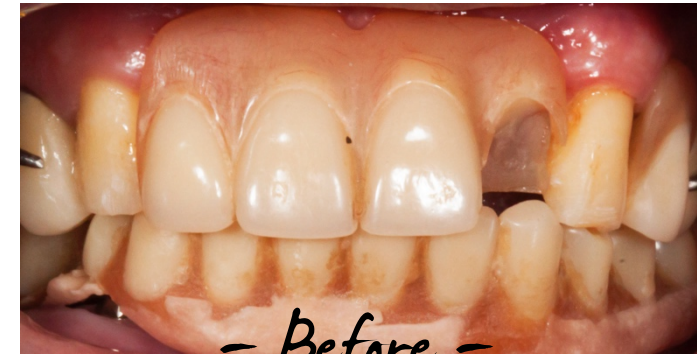DO YOU HAVE A CHALLENGING PATIENT CASE WITH THE NEED FOR A COMBINATION OF CONVENTIONAL PARTIAL DENTURE AGAINST A FULL ARCH REHABILITATION?

Here is the story of a patient who was referred to me by a general dentist.

Sometimes a patient may present to you with the need for a combination of different types of prosthetic treatment.

You may wish to save patient's teeth with good prognosis and decide to restore the partially edentulous span using conventional partial denture; and sometimes implants may be placed in non-ideal positions and you need to finish the prosthetic treatment with predictable long-term outcome.

If you encounter difficulties finishing the prosthetic treatment because of anatomic limitations, compromised planning and implant placement – he/she may benefit from the help of a Prosthodontist – Here is the story of my patient "Will"...



CONTINUE NEXT PAGE

Inside This Issue

CASE REPORT

Do you have a challenging patient case with the need for a combination of conventional partial denture against a full arch rehabilitation?
[PAGE 1-2]

CLINICAL DENTAL RESEARCH

Implant-borne restoration maintenance guidelines
[PAGE 3]

RECONSTRUCTIVE DENTAL SPECIALIST

About Dr. Lin
[PAGE 4]

WHEN SHOULD YOU CONSIDER REFERRING TO A PROSTHODONTIST?

Prosthodontists are specialists in esthetic, implant, and reconstructive dentistry.

1. Treatment complexity is beyond your typical practice.

Vertical dimension discrepancies, severely resorbed ridges, limited restorative space, poor implant angulation, TMJ, severe bruxism, traumatic tooth loss, or congenital abnormalities.

2. Patient has extensive needs and is draining too much of your chair time!

If your patient requires treatment from multiple specialists, we can help sequence and manage the interdisciplinary treatment plans.

3. Patient wants a perfect smile!

If the patient has a gummy smile, thin gum and susceptible to recession, or extremely picky!

4. You want to discuss a case with a colleague to ease your mind.

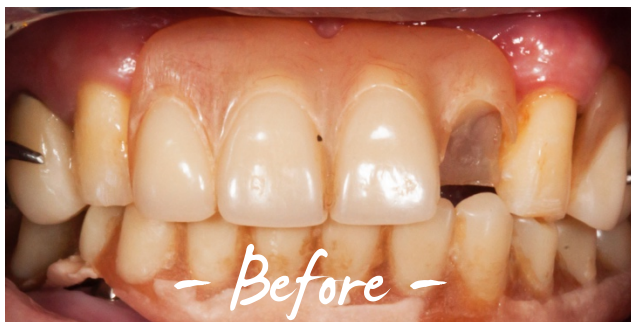We are an excellent resource for you to ask questions about complex treatments. We can work with you or complete the treatment for you to achieve the best in both function and esthetics for your patients.

DO YOU WANT TO CHAT ABOUT A COMPLEX PATIENT CASE? OR WOULD YOU LIKE TO MEET AND SHARE IDEAS?

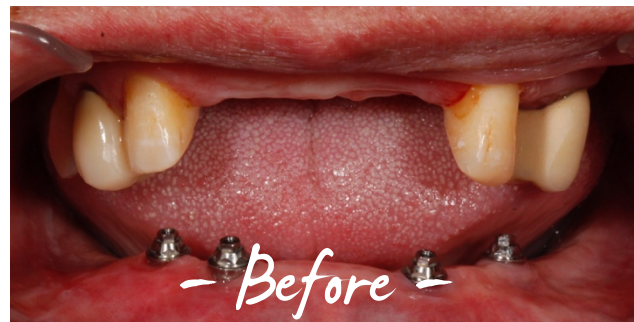With your reputation for quality dental service and my experience with complex treatments, we can work together and benefit as a team. We simply want to do what is best for the patients.

I would like to work with you on challenging patient cases and share knowledge and experience. I would love to meet you for lunch, over a coffee break, or at your office to discuss a difficult patient case or to share ideas.

Please don't hesitate to reach out to me. I'm looking forward to talking with you on the phone or meeting in person.



- Before -



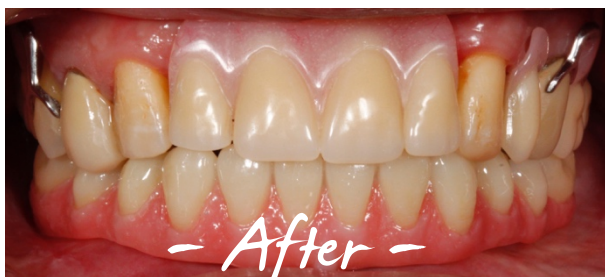- Before -

"Will" was referred to me because the general dentist did not feel comfortable restoring the lower osseointegrated implants with a full arch implant prosthesis against an upper partial denture.

The doctor was not sure about how to proceed with the additional treatment planning needed in order to meet the patient's esthetic and functional expectations.

The case was challenging because:

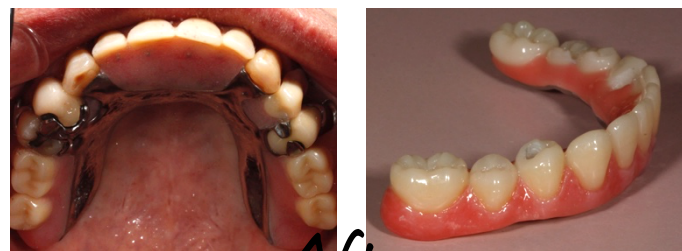
1. the restorative space was limited
2. the implant distribution was not ideal for the lower arch
3. the upper teeth required rest preparations and proximal plane modification in order to support and retain an upper partial denture properly
4. the occlusal plane was slightly compromised because of the retained existing teeth



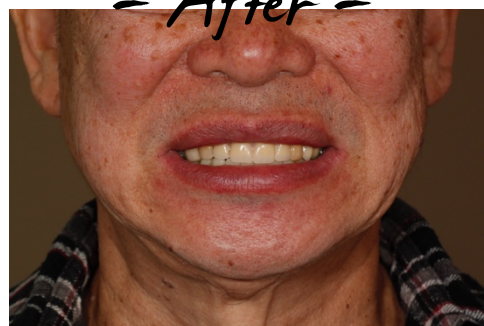- After -

Treatment:

- The anterior-posterior distribution of the dental implants were acceptable, but not ideal. The occlusal contacts were carefully evaluated in order to avoid excess contact force at the lower arch distal cantilevered span.
- We used monolithic composite/co-cr framework for the lower arch implant hybrid for strength and material compatibility against the upper conventional partial denture.
- The patient was extremely pleased with the result and is under routine maintenance and follow-up!



- After -



IMPLANT-BORNE RESTORATION MAINTENANCE GUIDELINES

1. Professional Maintenance

- ❖ Perform extraoral and intraoral health and dental exam of existing teeth and the implant prostheses.
- ❖ Professionally clean natural teeth, implant-borne and tooth-borne restorations, and implant abutments.
 - When metal abutment or implant thread is not exposed - conventional instrumentation is acceptable.
 - When abutment is exposed -
 - Plastic scaling instrument
 - Powered glycine powder air polishing system (e.g. Hu-Friedy Air-Flow)
 - Implant-specific ultrasonic tip
 - Conventional instrumentation to debride the prosthetic portion (above the abutment)
 - If implant thread is exposed -
 - Refer to a periodontist for possible implant surface treatment.
 - Use of titanium metal instruments with compatible material hardness for scaling and debridement.
- ❖ Application of chlorhexidine gluconate as a topical agent.
 - Oral rinse (e.g. Peridex 0.12%)
 - 1% CHX gel at implant-abutment junction for moderate to high risk patients.
- ❖ Reassess the prosthetic contours to facilitate at-home maintenance.
- ❖ Prosthetic components that compromise function should be adjusted, repaired, or remade as needed. Please contact me.

2. Patient Education and At-home Maintenance

- ❖ Patient with multiple and complex restorations should be given detailed oral hygiene instructions.
 - 0.3% triclosan-containing toothpaste (i.e. Colgate Total) - reduces soft tissue inflammation and peri-implant mucositis
 - Consider adding short-term use of chlorhexidine gluconate when indicated.
 - Denture acrylic resin for fixed hybrids would need to be brushed with a non-abrasive denture toothpaste (e.g. Cleanadent Paste - can be used inside and outside of the mouth!)
- ❖ Recommend oral hygiene aids such as floss, water flossers, air flossers, interdental cleaners, and electric toothbrushes.
- ❖ Occlusal devices should be worn during sleep, and clean with proper cleaning agent.
- ❖ Implant-borne removable prostheses need to be removed and cleaned during sleep.

3. Patient Recare

- ❖ Exam every 6 months as a lifelong regimen
- ❖ High-risk patients (e.g. parafunctional chewing habit, smoker, diabetic, thin gingival biotype, poor home-care motivation)
 - 3 months recare for the 1st year following prosthesis delivery and continue the same frequency until tissues and prosthesis appear stable

MY TREATMENT SUMMARY FOR WILL:

- ❖ Comprehensive evaluation and diagnostic work-up
- ❖ Teeth modifications based on the partial denture design
- ❖ Accurate final impressions and properly mount the working casts to determine occlusal contacts and manage occlusal forces
- ❖ Completion of the upper partial denture and lower implant hybrid prosthesis
- ❖ Regular maintenance re-care visits

WOULD YOU LIKE TO STAY UP TO DATE WITH THE MOST CURRENT CLINICAL DENTAL RESEARCH?

You are not alone for continuing education! You have the opportunity to join like-minded clinicians in the community and challenge yourself to learn in a friendly non-judgmental atmosphere. We would love to have you for study club events, lecture presentations, and treatment planning seminars. For more detail on future events, please contact me.